

A. Volna

Гвоздь для голени – всё ещё «золотой стандарт»?

Избранные вопросы лечения около и внутрисуставных переломов
Волгоград, 15 декабря 2017 года



- **Gold standard for tibial shaft fractures**
- **Possible in proximal and distal tibial fractures with appropriate technique and implants**
- **Reaming is accepted for all but G&A type 3C open fractures [controversial]**

Inan M., Halici M., Ayan I., Tuncel M., Karaoglu S.

Treatment of type IIIA open fractures of tibial shaft with Ilizarov external fixator versus unreamed tibial nailing

Arch Orthop Trauma Surg, 2007:(127):617-23

Larsen LB, Madsen JE, Hoiness PR, Ovre S

Should insertion of intramedullary nails for tibial fractures be with or without reaming? A prospective, randomized study with 3.8 years' follow-up

J Orthop Trauma, 2004:(18):144-9

Ziran BH, Darowish M, Klatt BA, Agudelo JF, Smith WR

Intramedullary nailing in open tibia fractures: a comparison of two techniques

Int Orthop, 2004:(28):235-8

IMN. Why IMN is so great?

- **MINIINVASIVE**
 - Historical starting point of trend
 - Soft-tissue friendly
- **MECHANICALLY SUPERIOR**
 - Spreads load along endosteum rather than fixed points of screw/plate/cortex interface
 - Load sharing
 - Withstand greater bending forces
- **TECHNICALLY FORGIVING**
 - Realign fracture secondary to intramedullary position
 - Extensive experience with shaft fractures
 - New kinds of IMN for very proximal and distal fractures

Inan M., Halici M., Ayan I., Tuncel M., Karaoglu S.

Treatment of type IIIA open fractures of tibial shaft with Ilizarov external fixator versus unreamed tibial nailing

Arch Orthop Trauma Surg, 2007:(127):617-23

Larsen LB, Madsen JE, Hoiness PR, Ovre S

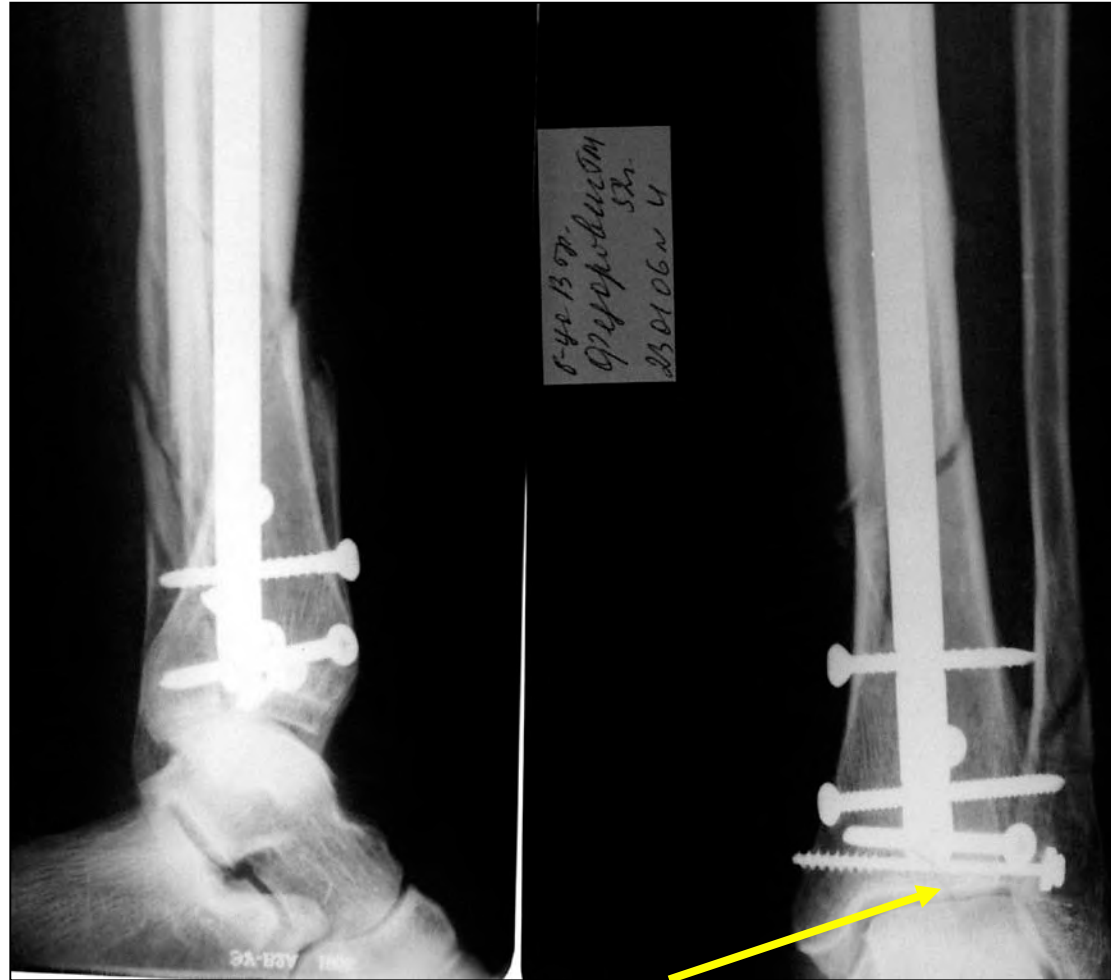
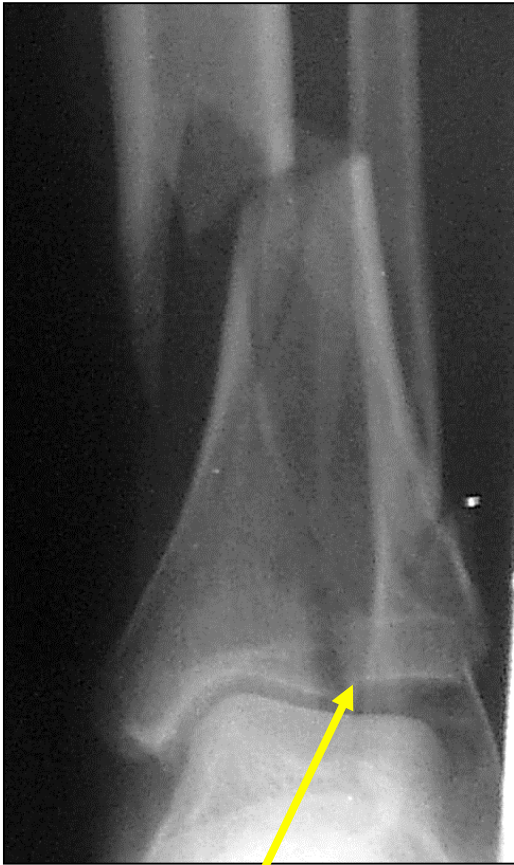Should insertion of intramedullary nails for tibial fractures be with or without reaming? A prospective, randomized study with 3.8 years' follow-up

J Orthop Trauma, 2004:(18):144-9

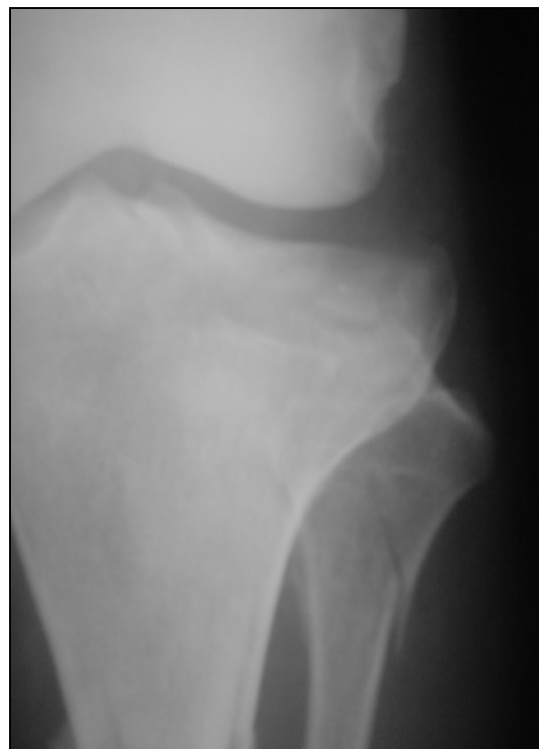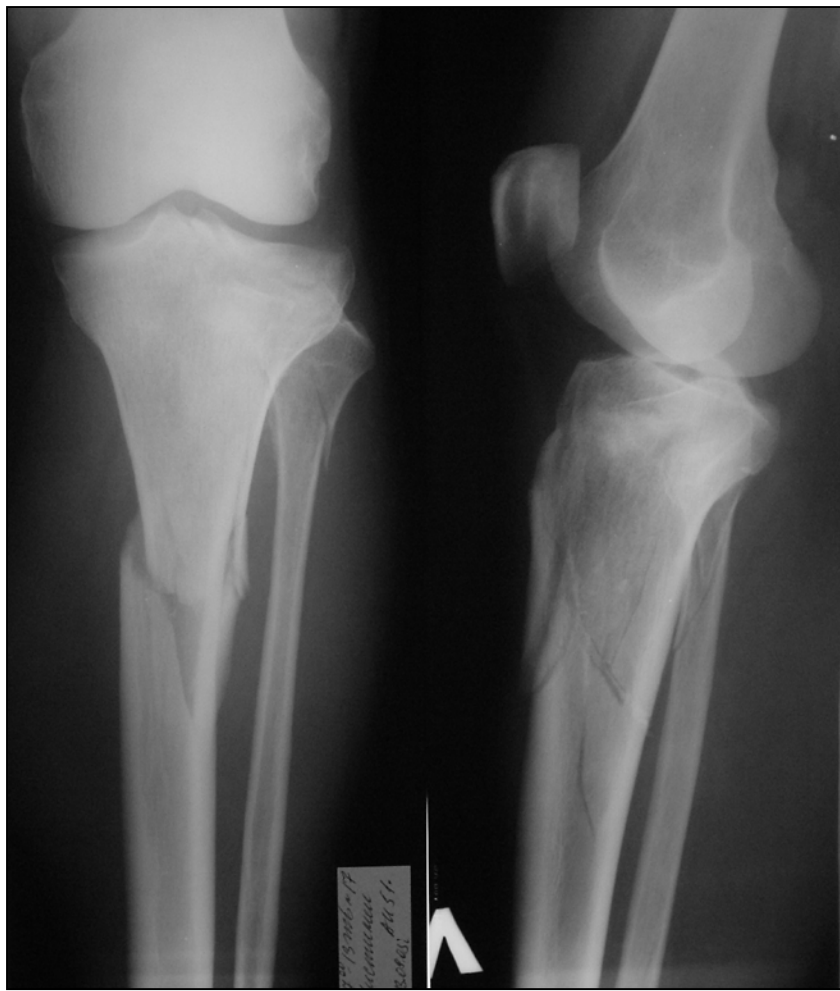Ziran BH, Darowish M, Klatt BA, Agudelo JF, Smith WR

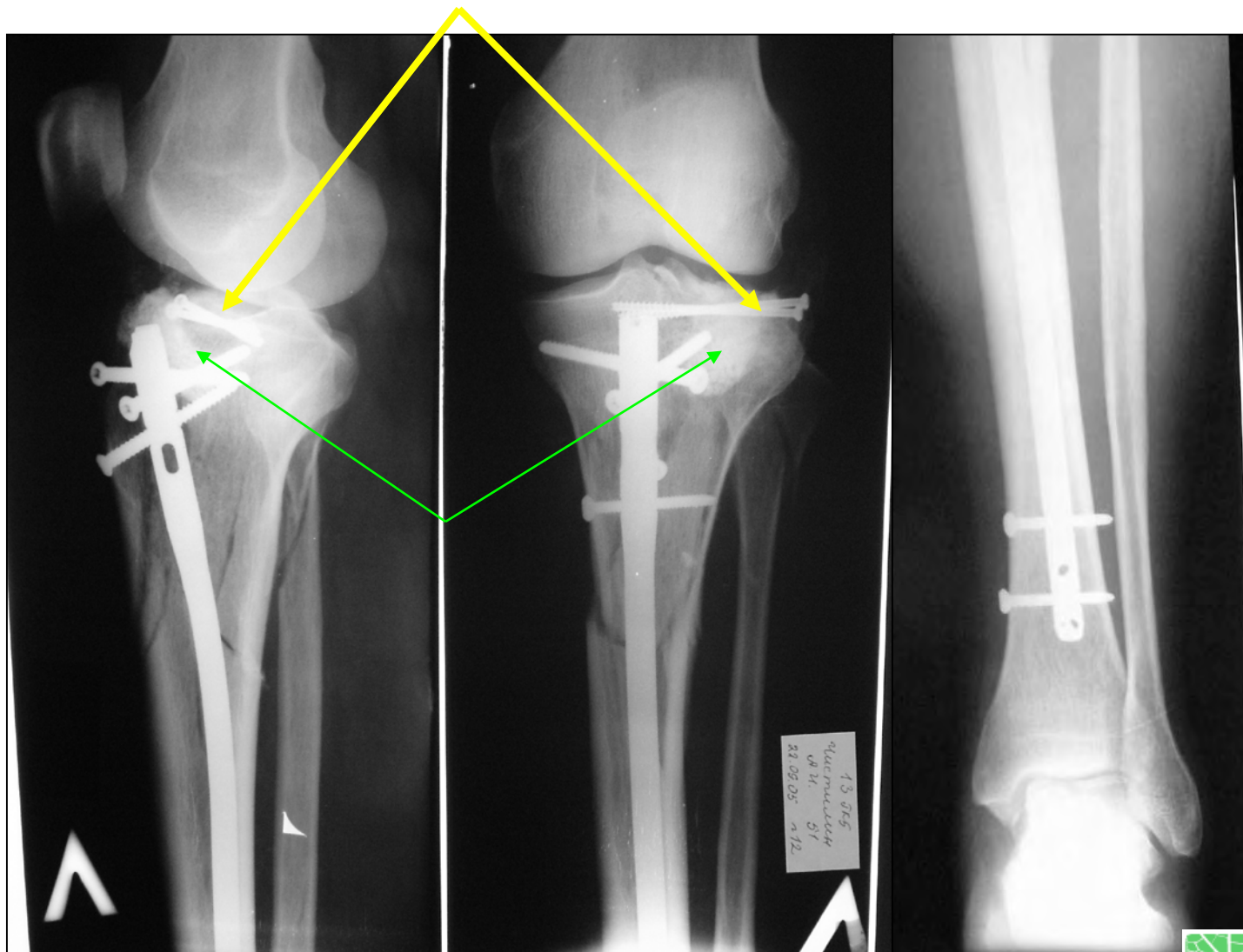
Intramedullary nailing in open tibia fractures: a comparison of two techniques

Int Orthop, 2004:(28):235-8

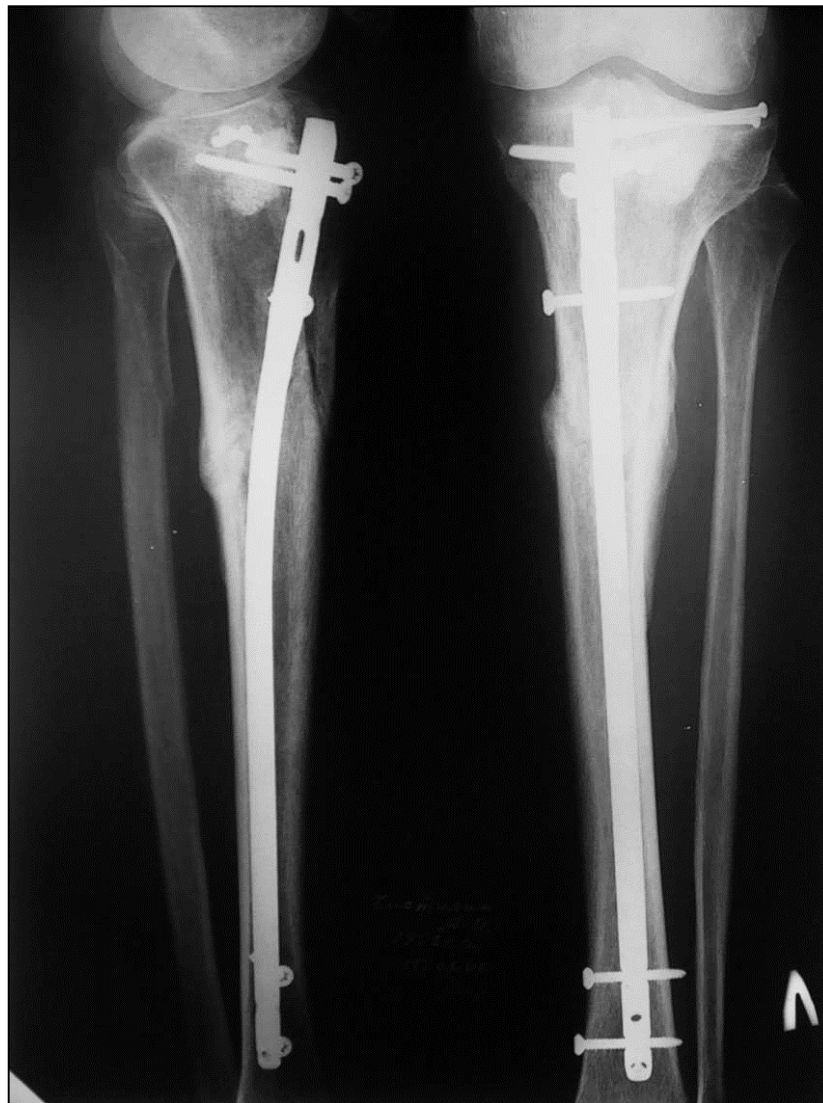

Courtesy of
A. Semenisty





Should we always follow this trend?



Courtesy of
A. Semenisty

Aims and objectives

- Remind about the importance of AKP syndrome after IMN
- Discuss indications for plating and nailing
- Understand the basis of choosing the appropriate surgical techniques (their advantages and disadvantages)

Anterior Knee Pain after nailing

- 16 patients (36%) were painless, 16 (36%) had mild pain, and 13 (28%) had moderate to severe pain (**AKP – 64%**)

Anterior Knee Pain After Tibial Intramedullary Nailing Using a Medial Paratendinous Approach

Song, Si Young; Chang, Ho Geun; Byun, Jae Chul; Kim, Tae Young
Journal of Orthopaedic Trauma Volume 26(3), March 2012, p 172-177

Anterior Knee Pain after nailing

- 16 patients (36%) were painless, 16 (36%) had mild pain, and 13 (28%) had moderate to severe pain (**AKP – 64%**)
- Fourteen (**AKP – 67%**) of the twenty-one patients treated with transtendinous nailing reported anterior knee pain at the final evaluation.

Anterior knee pain after intramedullary nailing of fractures of the tibial shaft. A prospective, randomized study comparing two different nail-insertion techniques.

Toivanen JA, Vaisto O, Kannus P, et al.. J Bone Joint Surg Am. 2002;84:580-585.

Anterior Knee Pain After Tibial Intramedullary Nailing Using a Medial Paratendinous Approach

Song, Si Young; Chang, Ho Geun; Byun, Jae Chul; Kim, Tae Young
Journal of Orthopaedic Trauma Volume 26(3), March 2012, p 172-177

Anterior Knee Pain after nailing

- 16 patients (36%) were painless, 16 (36%) had mild pain, and 13 (28%) had moderate to severe pain (**AKP – 64%**)
- Fourteen (**AKP – 67%**) of the twenty-one patients treated with transtendinous nailing reported anterior knee pain at the final evaluation.
- The group includes 11 retrospective and 9 prospective studies (total 1469 fractures).
- The mean follow-up was 23.9 months. The mean incidence of anterior knee pain at the end of the follow-up was **47.4%**

Incidence and aetiology of anterior knee pain after intramedullary nailing of the femur and tibia.

Katsoulis E, Court-Brown C, Giannoudis PV

J Bone Joint Surg Br. 2006;88:576-580

Anterior knee pain after intramedullary nailing of fractures of the tibial shaft. A prospective, randomized study comparing two different nail-insertion techniques.

Toivanen JA, Vaisto O, Kannus P, et al.. J Bone Joint Surg Am.

2002;84:580-585.

Anterior Knee Pain After Tibial Intramedullary Nailing Using a Medial Paratendinous Approach

Song, Si Young; Chang, Ho Geun; Byun, Jae Chul; Kim, Tae Young

Journal of Orthopaedic Trauma Volume 26(3), March 2012, p 172-177

Anterior Knee Pain after nailing. Aetiology

- Nail removal doesn't remove pain completely

Incidence and aetiology of anterior knee pain after intramedullary nailing of the femur and tibia.

Katsoulis E, Court-Brown C, Giannoudis PV

J Bone Joint Surg Br. 2006;88:576-580

Anterior knee pain after intramedullary nailing of fractures of the tibial shaft. A prospective, randomized study comparing two different nail-insertion techniques.

Toivanen JA, Vaisto O, Kannus P, et al.. J Bone Joint Surg Am.

2002;84:580-585.

Anterior Knee Pain After Tibial Intramedullary Nailing Using a Medial Paratendinous Approach

Song, Si Young; Chang, Ho Geun; Byun, Jae Chul; Kim, Tae Young

Journal of Orthopaedic Trauma Volume 26(3), March 2012, p 172-177

Anterior Knee Pain after nailing. Aetiology

- Nail prominence
- Transtendinous approach
- Violation of patellofemoral joint kinematics
- Damage to the medial meniscus and the ligamentum transversum
- Impingement of the infrapatellar fat pad
- Injury to the infrapatellar branch of the saphenous nerve
- Penetration of articular surface
- Etc.

Incidence and aetiology of anterior knee pain after intramedullary nailing of the femur and tibia.

Katsoulis E, Court-Brown C, Giannoudis PV

J Bone Joint Surg Br. 2006;88:576-580

Anterior knee pain after intramedullary nailing of fractures of the tibial shaft. A prospective, randomized study comparing two different nail-insertion techniques.

Toivanen JA, Vaisto O, Kannus P, et al.. J Bone Joint Surg Am.

2002;84:580-585.

Anterior Knee Pain After Tibial Intramedullary Nailing Using a Medial Paratendinous Approach

Song, Si Young; Chang, Ho Geun; Byun, Jae Chul; Kim, Tae Young

Journal of Orthopaedic Trauma Volume 26(3), March 2012, p 172-177

Anterior Knee Pain after nailing. Aetiology

- Nail prominence
- Transtendinous approach
- Violation of patellofemoral joint kinematics
- Damage to the medial meniscus and the ligamentum transversum
- Impingement of the infrapatellar fat pad
- Injury to the infrapatellar branch of the saphenous nerve
- Penetration of articular surface
- Etc.

Incidence and aetiology of anterior knee pain after intramedullary nailing of the femur and tibia.

Katsoulis E, Court-Brown C, Giannoudis PV

J Bone Joint Surg Br. 2006;88:576-580

Anterior knee pain after intramedullary nailing of fractures of the tibial shaft. A prospective, randomized study comparing two different nail-insertion techniques.

Toivanen JA, Vaisto O, Kannus P, et al.. J Bone Joint Surg Am.

2002;84:580-585.

Anterior Knee Pain After Tibial Intramedullary Nailing Using a Medial Paratendinous Approach

Song, Si Young; Chang, Ho Geun; Byun, Jae Chul; Kim, Tae Young

Journal of Orthopaedic Trauma Volume 26(3), March 2012, p 172-177

Anterior Knee Pain after nailing. Aetiology

- **Injury to the infrapatellar branch of the saphenous nerve**

Incidence and aetiology of anterior knee pain after intramedullary nailing of the femur and tibia.

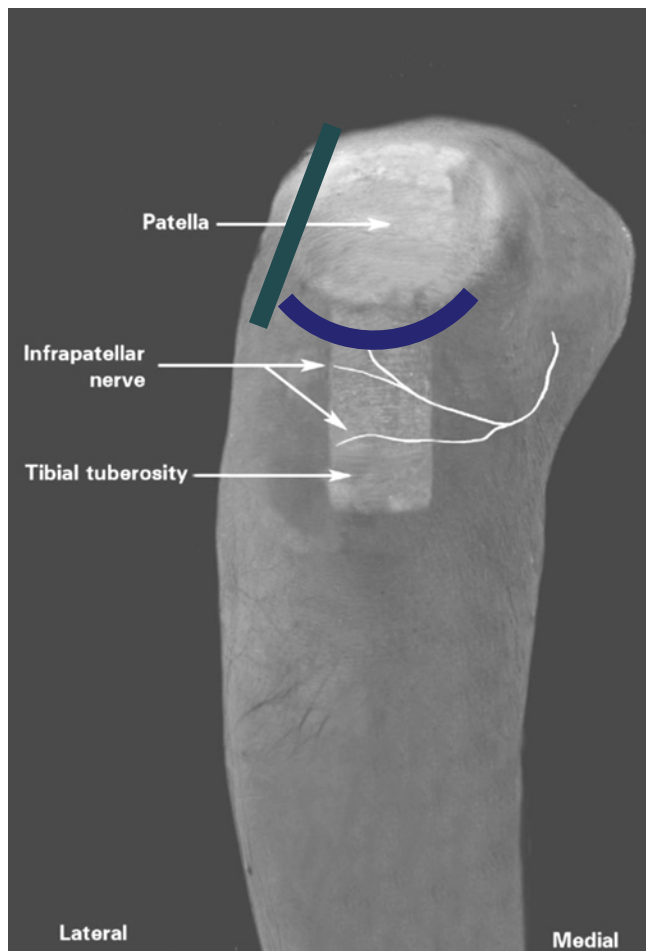
Katsoulis E, Court-Brown C, Giannoudis PV
J Bone Joint Surg Br. 2006;88:576-580

Anterior Knee Pain After Tibial Intramedullary Nailing Using a Medial Paratendinous Approach

Song, Si Young; Chang, Ho Geun; Byun, Jae Chul; Kim, Tae Young
Journal of Orthopaedic Trauma Volume 26(3), March 2012, p 172-177

Anterior Knee Pain after nailing. Aetiology

Study shows that direct iatrogenic injury to the infrapatellar nerve is associated with the postoperative chronic anterior knee pain



Injury, Int. J. Care Injured 43 (2012) 779–783

Contents lists available at SciVerse ScienceDirect

Injury

journal homepage: www.elsevier.com/locate/injury



Injury to the infrapatellar branch of the saphenous nerve, a possible cause for anterior knee pain after tibial nailing?

M.S. Leliveld, M.H.



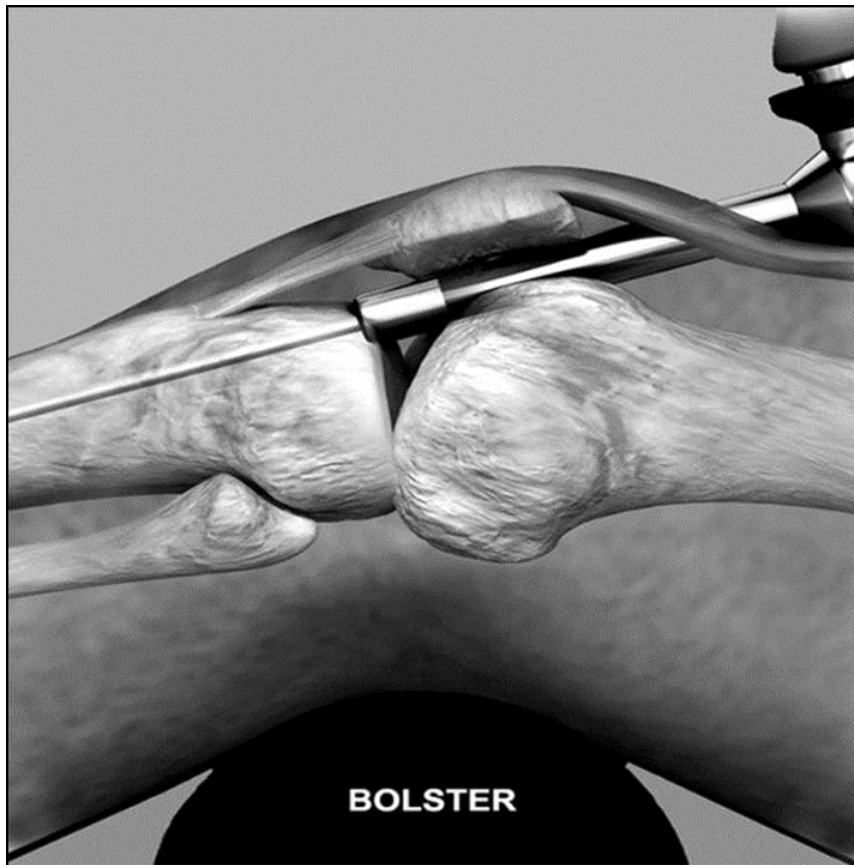
Anterior Knee Pain after nailing. Approach

2016

- Comparison of patellar tendon splitting (PTS), medial parapatellar (MPP) approach and lateral semiextended approach

- In this adequately-powered study, at minimum 1 year followup there were ***no statistically significant differences*** between any of the three surgical approaches in knee pain severity, location, or overall knee function...

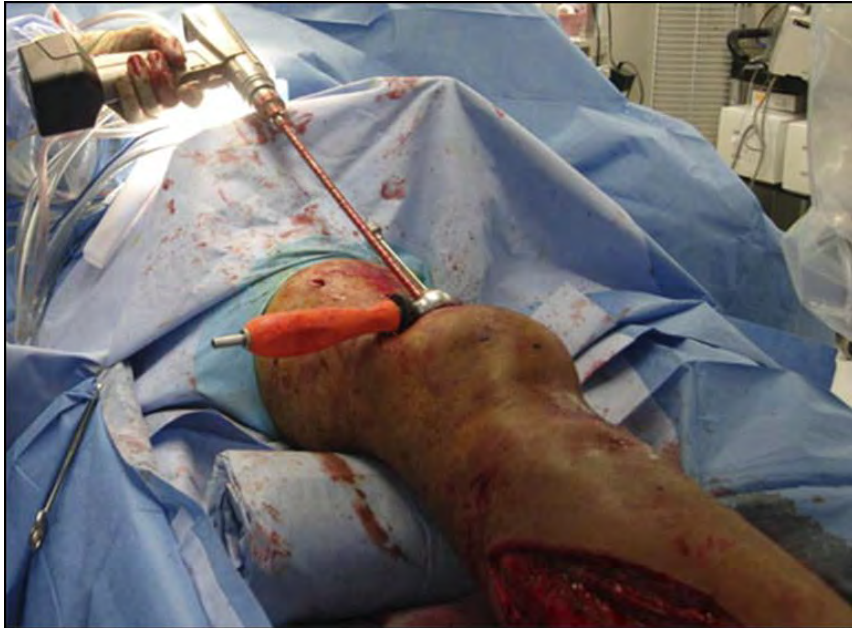Anterior Knee Pain after nailing. Suprapatellar approach



- Gelbke MK, Coombs D, Powell S, et al.. **Suprapatellar versus infra-patellar intramedullary nail insertion of the tibia: a cadaveric model for comparison of patellofemoral contact pressures and forces.** J Orthop Trauma. 2010;24:665-671.
- Eastman J, Tseng S, Lo E, et al.. **Retropatellar technique for intramedullary nailing of proximal tibia fractures: a cadaveric assessment.** J Orthop Trauma. 2010;24:672-676.
- Eastman JG, Tseng SS, Lee MA, et al.. **The retropatellar portal as an alternative site for tibial nail insertion: a cadaveric study.** J Orthop Trauma. 2010;24:659-664.

Dr. Dean Cole

Anterior Knee Pain after nailing. Suprapatellar approach



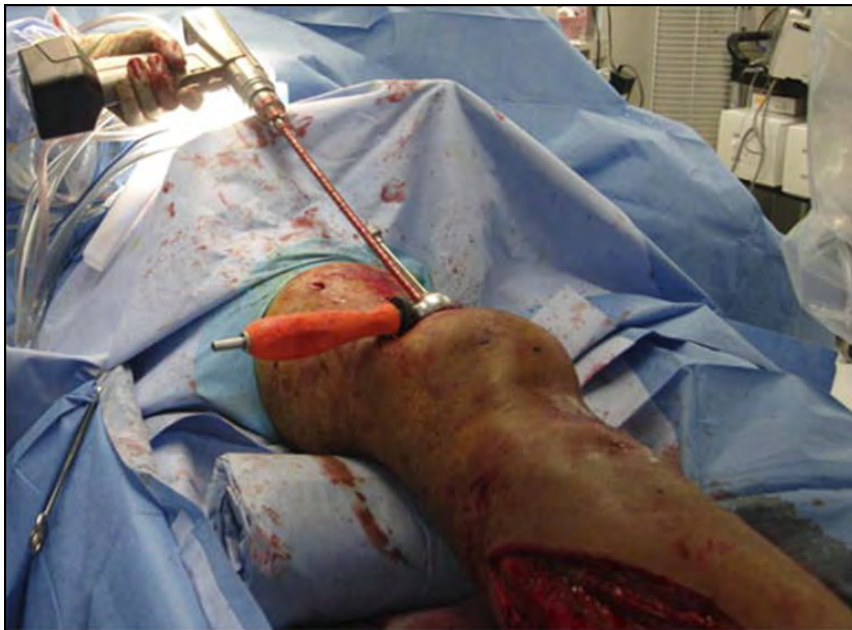Semiextended Intramedullary Nailing of the Tibia Using a Suprapatellar Approach: Radiographic Results and Clinical Outcomes at a Minimum of 12 Months Follow-up.

Sanders, Roy; DiPasquale, Thomas; Jordan, Charles; Arrington, John; Sagi, H

Journal of Orthopaedic Trauma. 28
Supplement 8:S29-S39, August 2014.

Dr. Dean Cole

Anterior Knee Pain after nailing. Suprapatellar approach



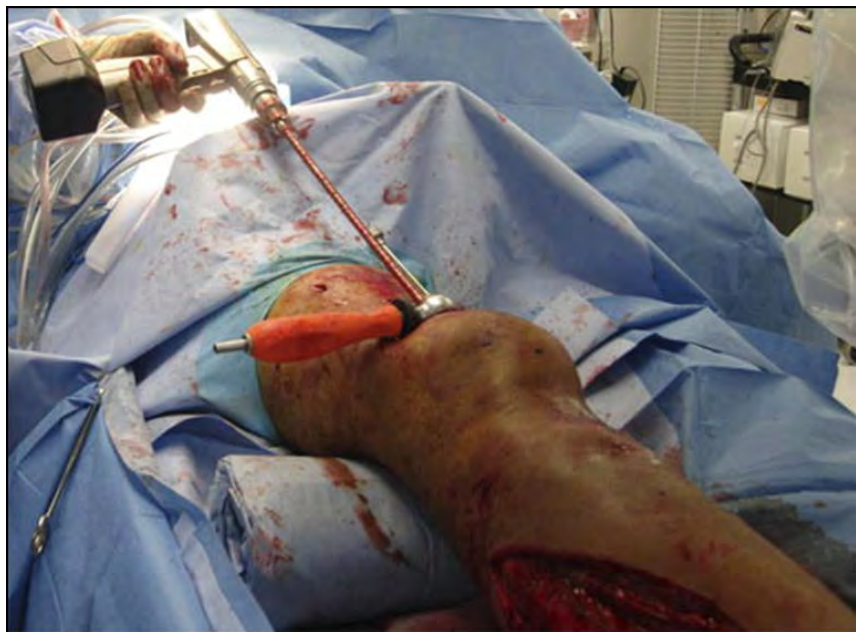Semiextended Intramedullary Nailing of the Tibia Using a Suprapatellar Approach: Radiographic Results and Clinical Outcomes at a Minimum of 12 Months Follow-up.

Sanders, Roy; DiPasquale, Thomas; Jordan, Charles; Arrington, John; Sagi, H

Journal of Orthopaedic Trauma. 28
Supplement 8:S29-S39, August 2014.

- Anterior Knee Pain:
35 of 36 patients
(97.2%) documented **no pain**

Anterior Knee Pain after nailing. Suprapatellar approach



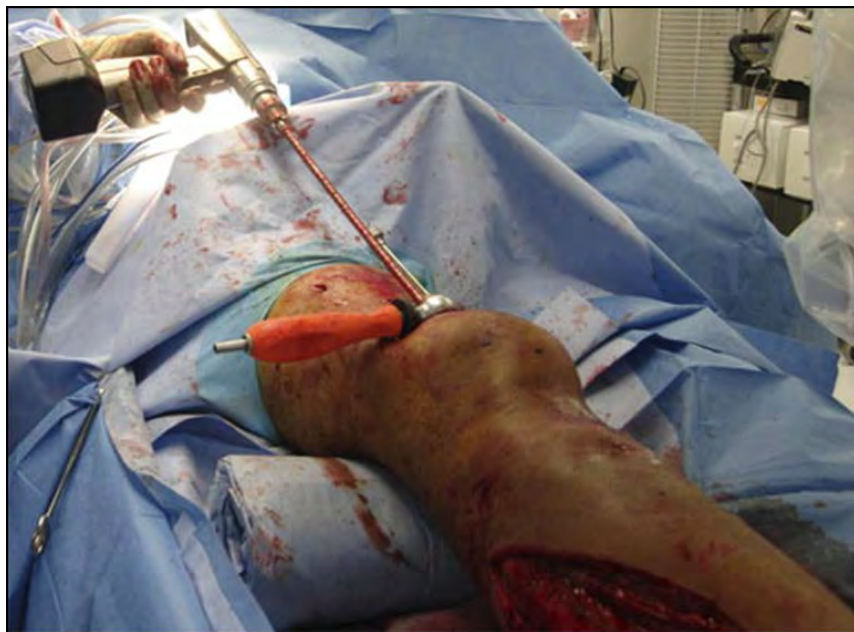Semiextended Intramedullary Nailing of the Tibia Using a Suprapatellar Approach: Radiographic Results and Clinical Outcomes at a Minimum of 12 Months Follow-up.

Sanders, Roy; DiPasquale, Thomas; Jordan, Charles; Arrington, John; Sagi, H

Journal of Orthopaedic Trauma. 28
Supplement 8:S29-S39, August 2014.

- Anterior Knee Pain:
35 of 36 patients
(97.2%) documented **no pain**
- “the procedure resulted in excellent tibial alignment, union, knee ROM, with no apparent sequelae in the PF joint based on immediate arthroscopy and 1-year MRI scans”

Anterior Knee Pain after nailing. Suprapatellar approach




Radiologic outcome and patient-reported function after intramedullary nailing: a comparison of the Retropatellar and Infrapatellar approach

Jones, Mark; Parry, Michael; Whitehouse, Michael; Mitchell, Steven

Journal of Orthopaedic Trauma Volume 28(5), May 2014, p 256-262

- Anterior Knee Pain:
Supra (retro) patellar approach – 27%
Infrapatellar approach – 28%
- “Retropatellar tibial nail insertion is not associated with more anterior knee pain when compared with infrapatellar nail insertion but is associated with more accurate nail fracture reduction.”



Anterior Knee Pain after nailing. Suprapatellar approach. New solution?



- Implant removal after suprapatellar nailing of the tibia is an unresolved problem
- Injuries may occur in the intra-articular structures of the knee joint during tibial nailing, such as transverse ligament of the knee, the medial meniscus, and the medial articular surface.
- Risk of knee infection

Anterior Knee Pain after nailing – still unresolved problem

IMN. Do you still believe it?

- **Gold standard for tibial shaft fractures**
- **Possible in proximal and distal tibial fractures with appropriate technique and implants**
- **Reaming is accepted for all but G&A type 3C open fractures [controversial]**

Inan M., Halici M., Ayan I., Tuncel M., Karaoglu S.

Treatment of type IIIA open fractures of tibial shaft with Ilizarov external fixator versus unreamed tibial nailing

Arch Orthop Trauma Surg, 2007:(127):617-23

Larsen LB, Madsen JE, Hoiness PR, Ovre S

Should insertion of intramedullary nails for tibial fractures be with or without reaming? A prospective, randomized study with 3.8 years' follow-up

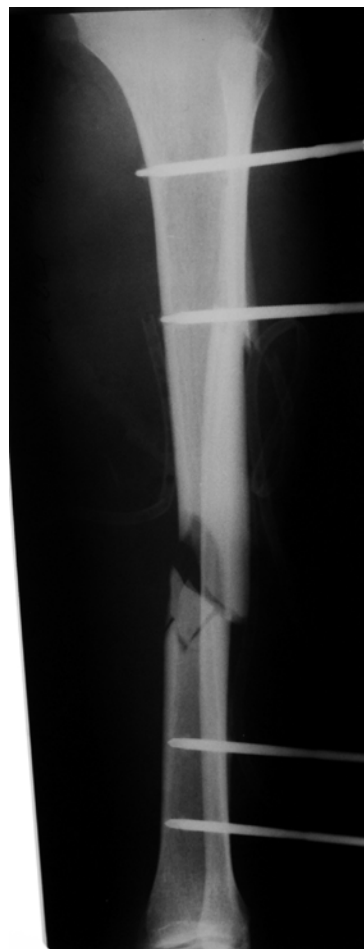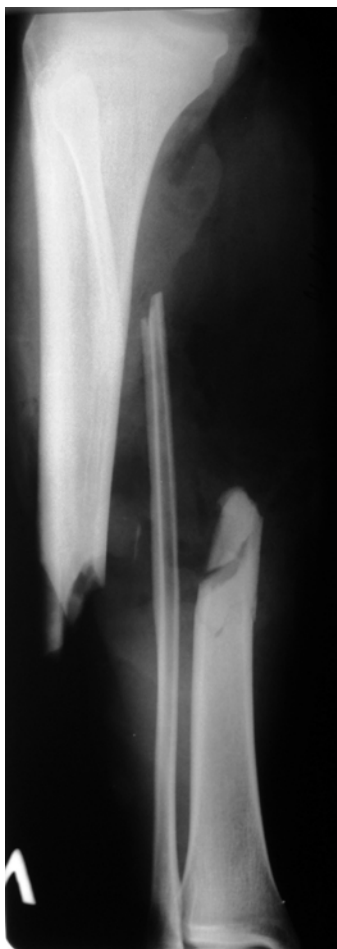
J Orthop Trauma, 2004:(18):144-9

Ziran BH, Darowish M, Klatt BA, Agudelo JF, Smith WR

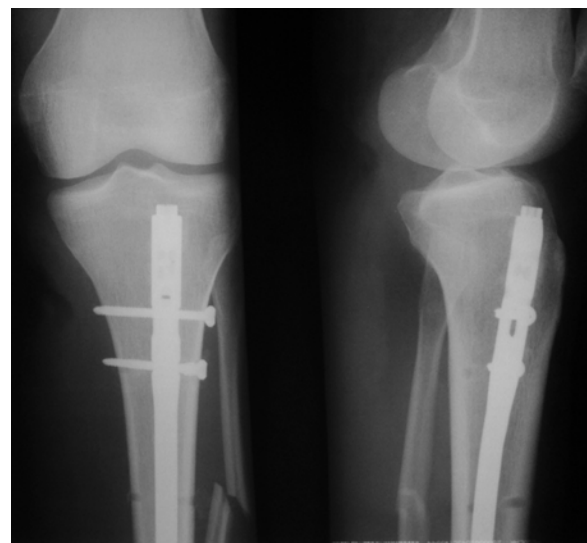
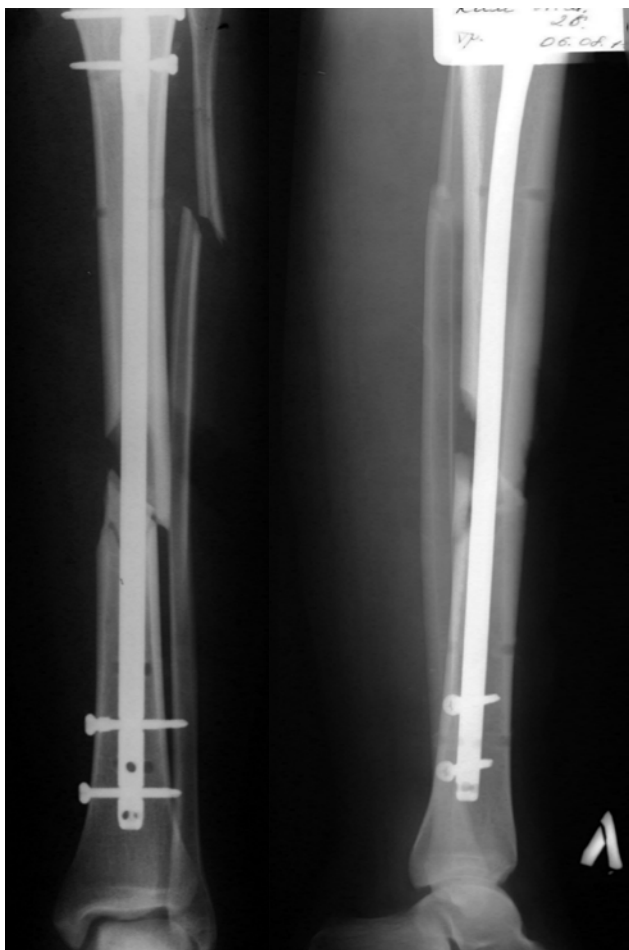Intramedullary nailing in open tibia fractures: a comparison of two techniques

Int Orthop, 2004:(28):235-8

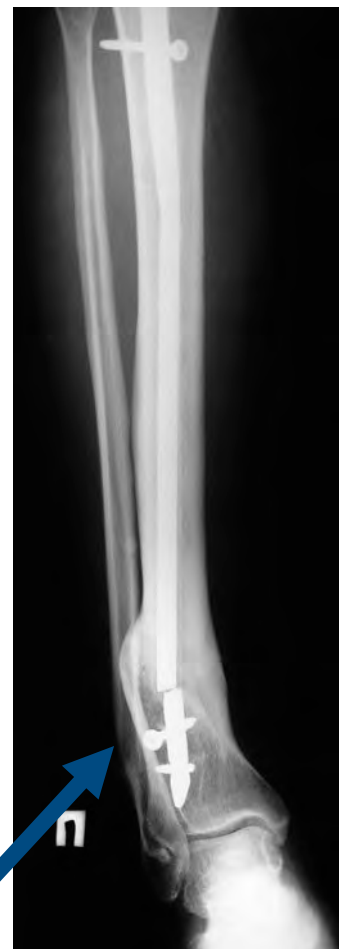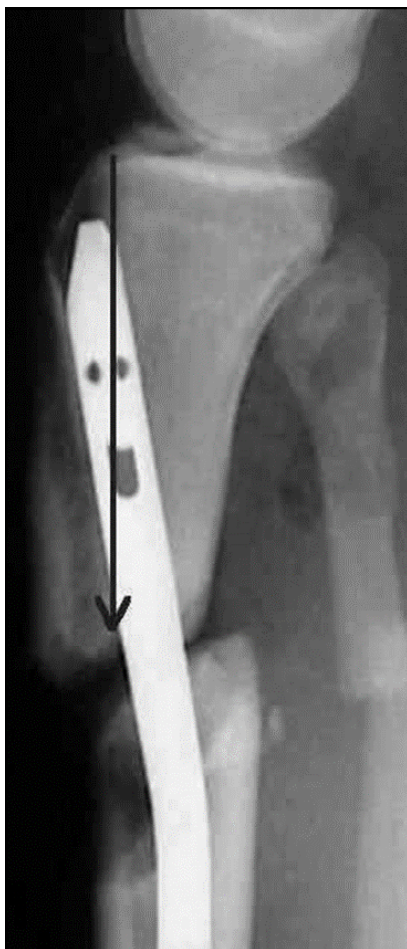
IMN. Do you still believe it?



IMN. Do you still believe it? Yes!



IMN. Do you still believe it? Yes! For all fractures?



Proximal Malalignment – Lang: up to 58%
Distal Malalignment – Vallier: up to 23%

Tibial shaft fractures. Algorithm of choosing surgical technique

High energy fractures

Low energy fractures

Tibial shaft fractures. Algorithm of choosing surgical technique

High energy fractures

Low energy fractures

Splinting

Bad soft tissue

Good soft tissue

Tibial shaft fractures. Algorithm of choosing surgical technique

High energy fractures

Low energy fractures

Splinting

Bad soft tissue

Good soft tissue

IMN

Tibial shaft fractures. Algorithm of choosing surgical technique

High energy fractures

Low energy fractures

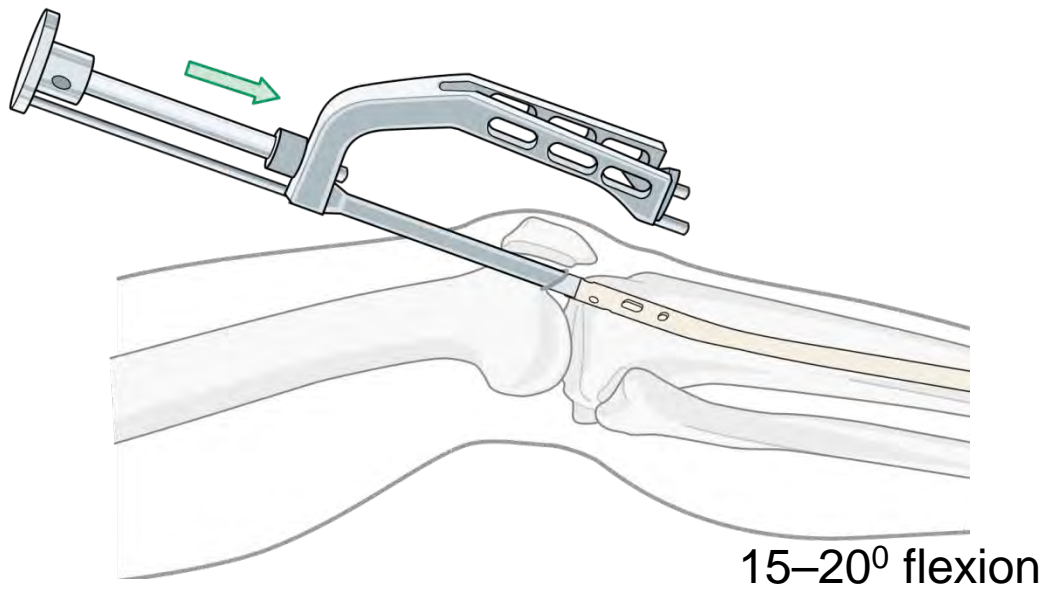
Splinting

Bad soft tissue

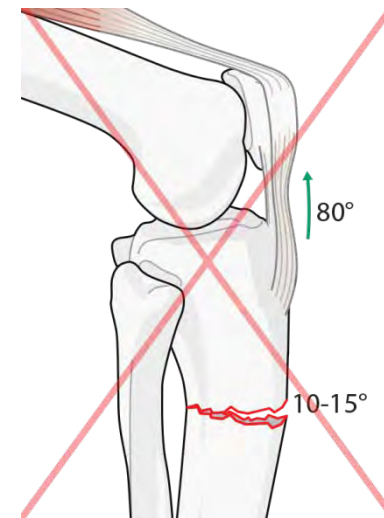
IMN

Proximal part

Semiextended or suprapatellar approach



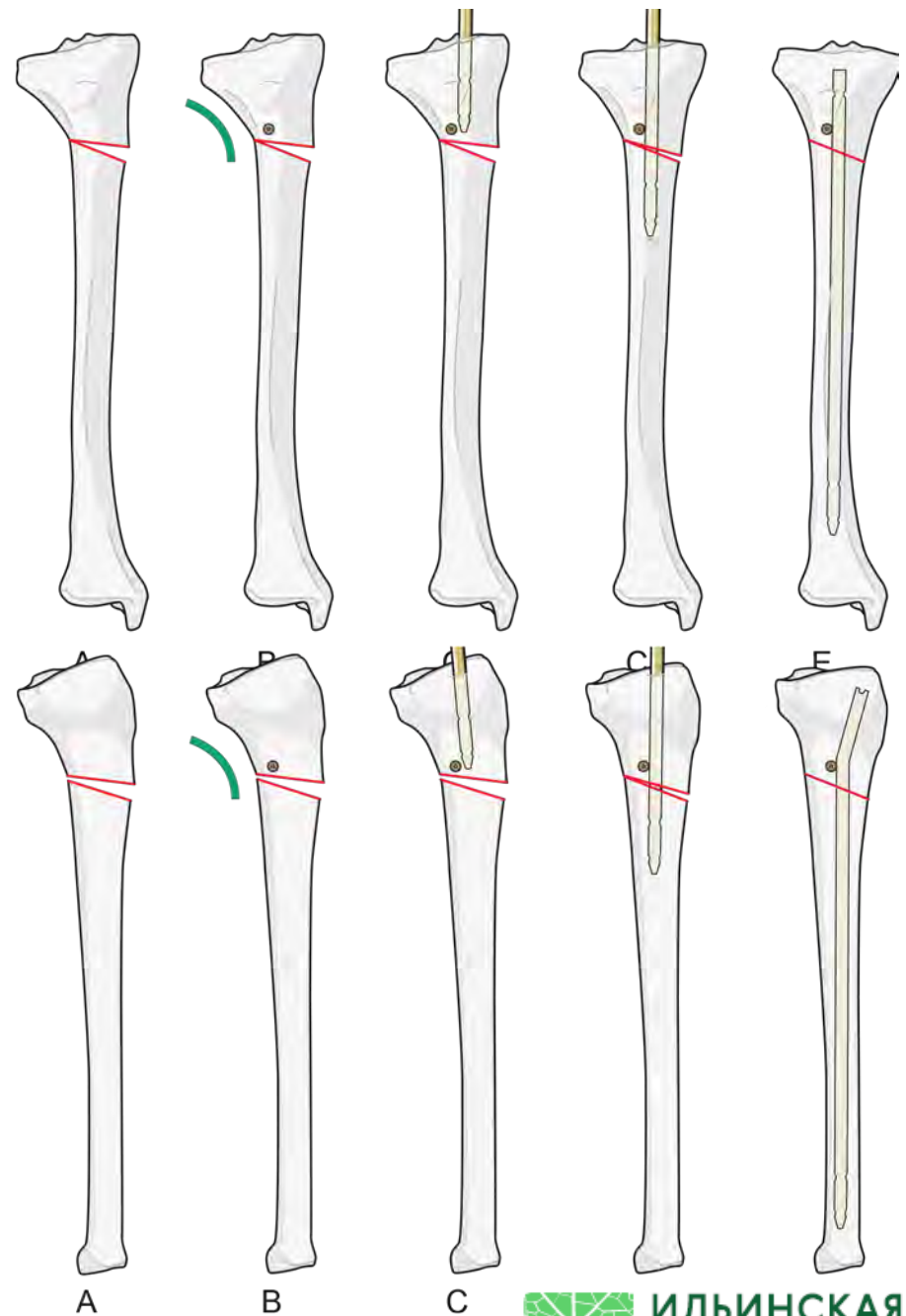
Medial parapatellar arthrotomy



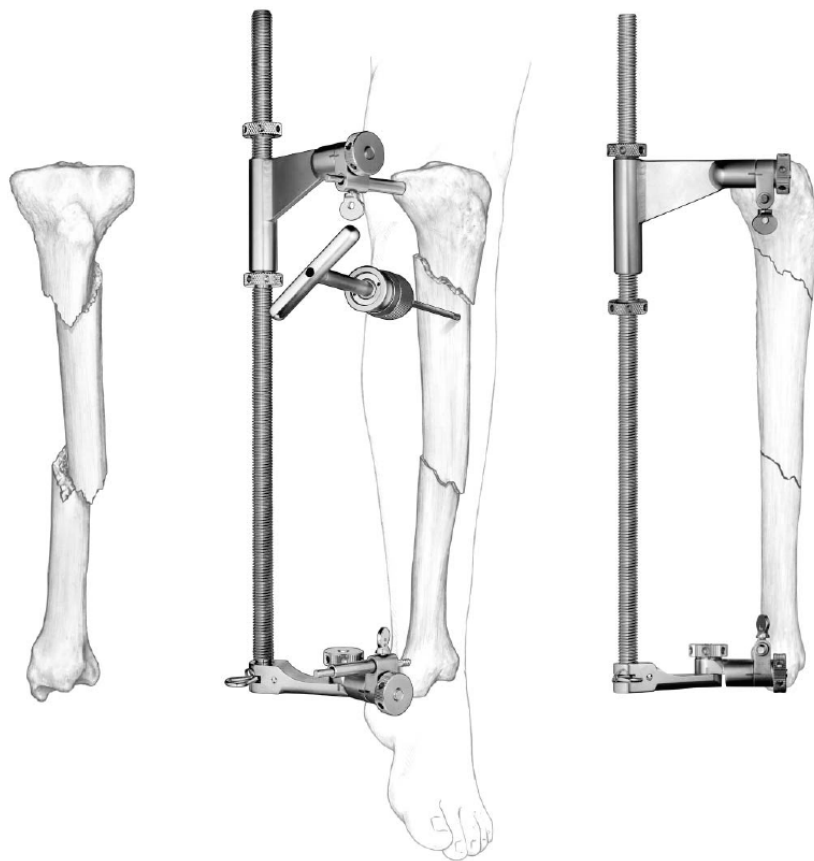
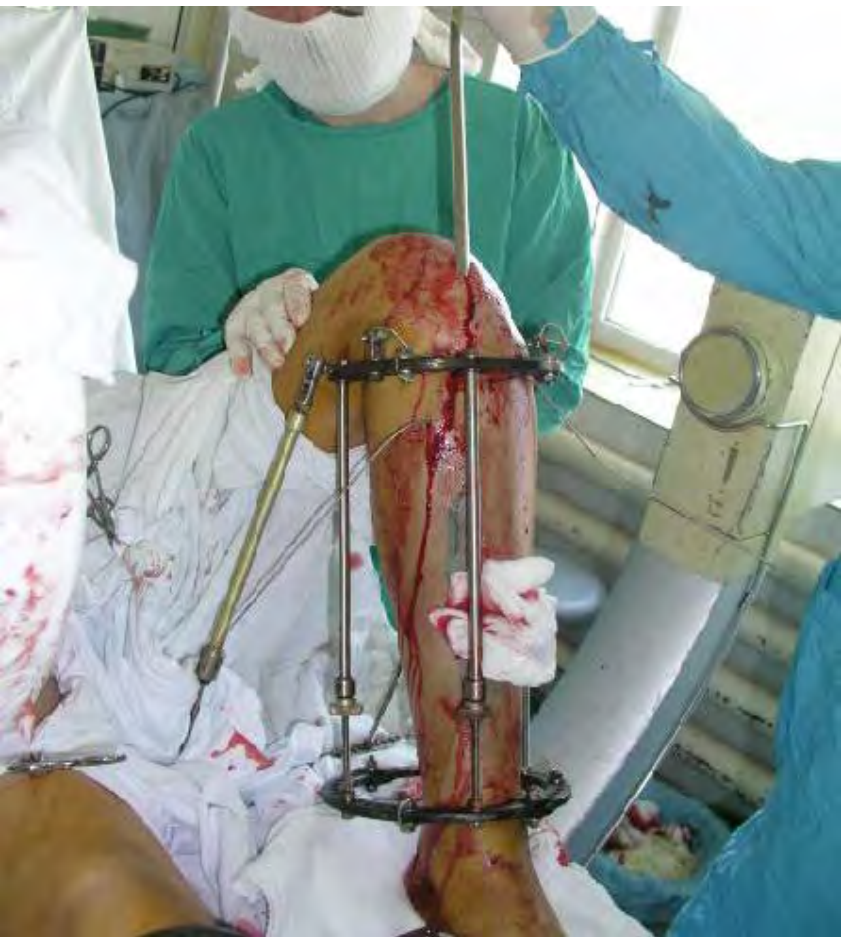Tornetta et al (*Clin Orthop Relat Res.* 1996;328:185–189)

Poller screws

- Block passage of nail from unwanted direction
- Screws placed on concave side of deformity
- Functionally narrows IM canal
- Increase strength and rigidity of fixation



Reduction



Tibial shaft fractures. Algorithm of choosing surgical technique

High energy fractures

Low energy fractures

Splinting

Bad soft tissue

IMN

Proximal part

Suprapatellar
or semiextended approach
Poller screws
ExFix for reduction

Middle part

Infrapatellar
approach

Tibial shaft fractures. Algorithm of choosing surgical technique

High energy fractures

Low energy fractures

Splinting

Bad soft tissue

IMN

Proximal part

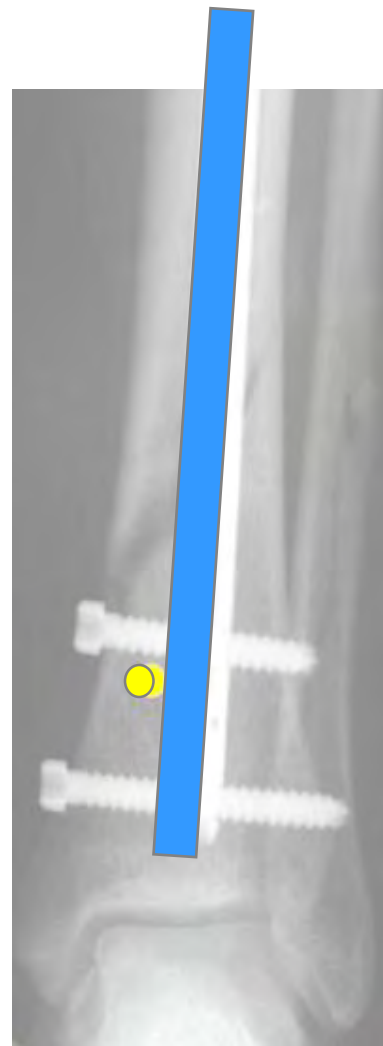


Suprapatellar
or semiextended approach
Poller screws
ExFix for reduction

Middle part

Infrapatellar
approach

Distal part

Blocking screw



Tibial shaft fractures. Algorithm of choosing surgical technique

High energy fractures

Low energy fractures

Splinting

Bad soft tissue

IMN

Proximal part

Suprapatellar
or semiextended approach
Poller screws
ExFix for reduction

Middle part

Infrapatellar
approach

Distal part

Infrapatellar
approach
Poller screws
ExFix for reduction
Fibular fixation

Tibial shaft fractures. Algorithm of choosing surgical technique

High energy fractures

Low energy fractures

Splinting

Bad soft tissue

Good soft tissue

IMN

Proximal part

Suprapatellar
or semiextended approach
Poller screws
ExFix for reduction

Middle part

Infrapatellar
approach

Distal part

Infrapatellar
approach
Poller screws
ExFix for reduction
Fibular fixation

Tibial shaft fractures. Algorithm of choosing surgical technique

High energy fractures

Low energy fractures

Splinting

Bad soft tissue

Good soft tissue

IMN

Proximal part

Suprapatellar
or semiextended approach
Poller screws
ExFix for reduction

Middle part

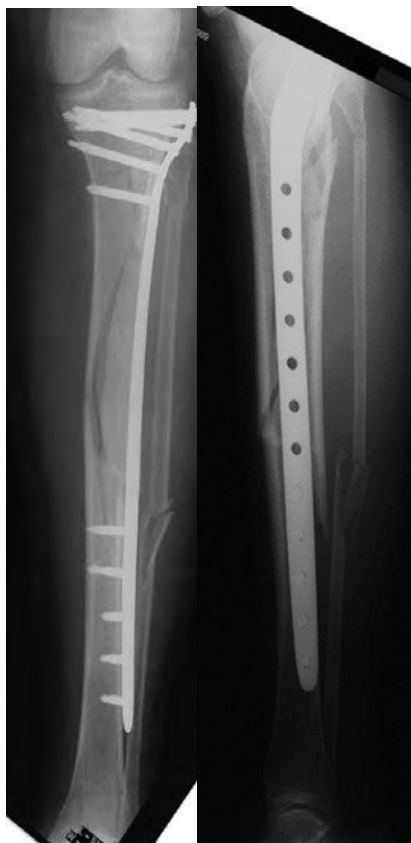Infrapatellar
approach

Distal part

Infrapatellar
approach
Poller screws
ExFix for reduction
Fibular fixation

IMN or Plating
(2nd choice)

High energy fracture, good soft tissue conditions



- Were no statistically significant differences between plating and nailing in fracture healing and knee motion
- Additional surgical reduction techniques were frequently needed with IMN
- Removal of implants seems to be more commonly needed with Plating

Lindvall, Eric; Sanders, Roy; DiPasquale, Thomas and al
Intramedullary Nailing versus percutaneous locked Plating of Extra-Articular Proximal Tibial Fractures: comparison of 56 cases

Journal of Orthopaedic Trauma

Volume 23(7), August 2009, pp 485-492

Benefits of plates for distal fractures

- Although nails may have benefits, especially mechanical, the ability to get a better reduction with a plate may be more important

- Less malalignment
- High union rate

Vallier et al (*J Orthop Trauma*. 2011;25:736–741)

Vallier et al, (*J Orthop Trauma*. 2012;26:327–332)

Tibial shaft fractures. Algorithm of choosing surgical technique

High energy fractures

Low energy fractures

Splinting

Splinting or compression

Bad soft tissue

Good soft tissue

IMN

Proximal part

Suprapatellar
or semiextended approach
Poller screws
ExFix for reduction

Middle part

Infrapatellar
approach

Distal part

Infrapatellar
approach
Poller screws
ExFix for reduction
Fibular fixation

IMN or Plating
(2nd choice)

Tibial shaft fractures. Algorithm of choosing surgical technique

High energy fractures

Low energy fractures

Splinting

Splinting or compression

Bad soft tissue

Good soft tissue

Poor bone quality

Good bone quality

IMN

Proximal part

Suprapatellar
or semiextended approach
Poller screws
ExFix for reduction

Middle part

Infrapatellar
approach

Distal part

Infrapatellar
approach
Poller screws
ExFix for reduction
Fibular fixation

IMN or Plating
(2nd choice)

Tibial shaft fractures. Algorithm of choosing surgical technique

High energy fractures

Low energy fractures

Splinting

Splinting or compression

Bad soft tissue

Good soft tissue

Poor bone quality

Good bone quality

IMN

Proximal part

Suprapatellar
or semiextended approach
Poller screws
ExFix for reduction

Middle part

Infrapatellar
approach

Distal part

Infrapatellar
approach
Poller screws
ExFix for reduction
Fibular fixation

IMN or Plating
(2nd choice)

IMN or Plating
(2nd choice)

Tibial shaft fractures. Algorithm of choosing surgical technique

High energy fractures

Low energy fractures

Splinting

Splinting or compression

Bad soft tissue

Good soft tissue

Poor bone quality

Good bone quality

IMN

Proximal part

Suprapatellar
or semiextended approach
Poller screws
ExFix for reduction

Middle part

Infrapatellar
approach

Distal part

Infrapatellar
approach
Poller screws
ExFix for reduction
Fibular fixation

IMN or Plating
(2nd choice)

IMN or Plating
(2nd choice)

Simple fracture

***Wedge, complex
fracture***

Tibial shaft fractures. Algorithm of choosing surgical technique

High energy fractures

Low energy fractures

Splinting

Splinting or compression

Bad soft tissue

Good soft tissue

Poor bone quality

Good bone quality

IMN

Proximal part

Suprapatellar
or semiextended approach
Poller screws
ExFix for reduction

Middle part

Infrapatellar
approach

Distal part

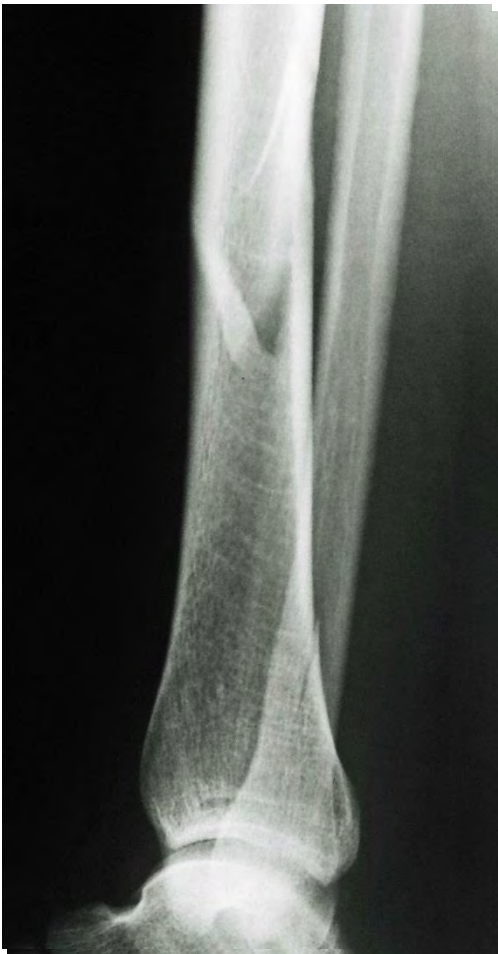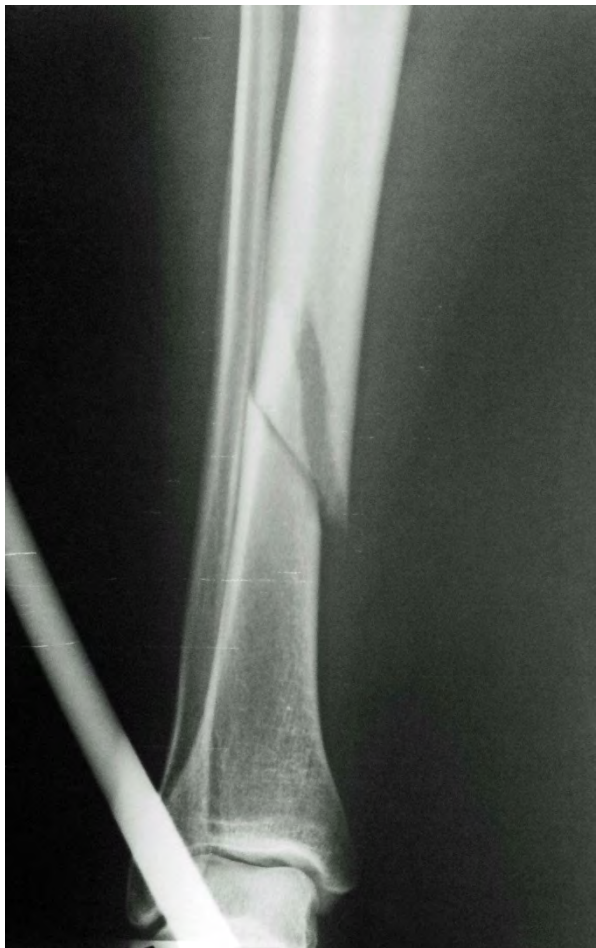Infrapatellar
approach
Poller screws
ExFix for reduction
Fibular fixation

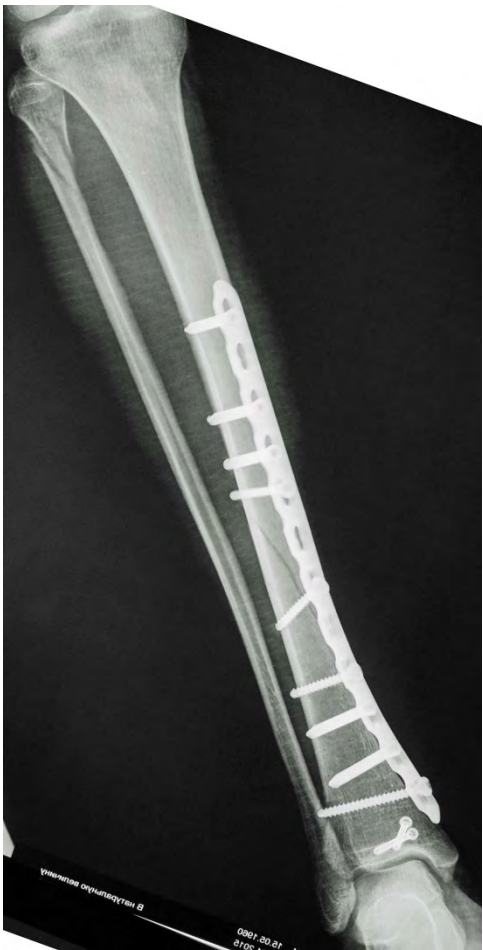IMN or Plating
(2nd choice)

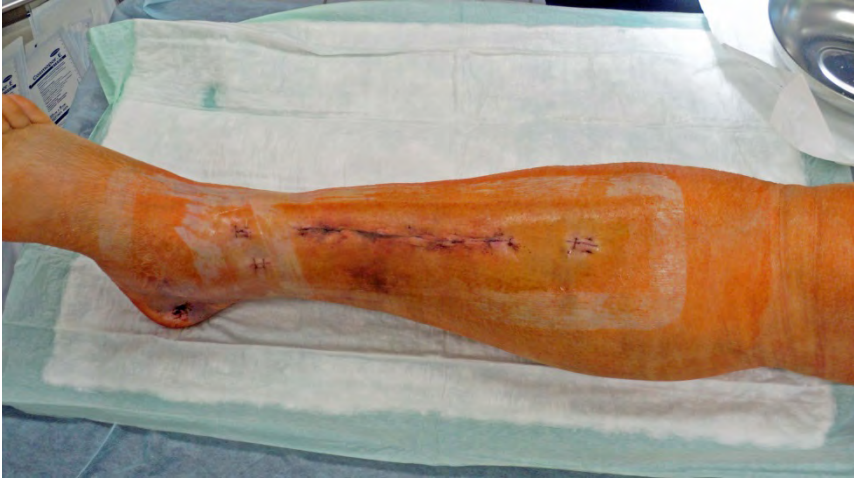IMN

Simple fracture

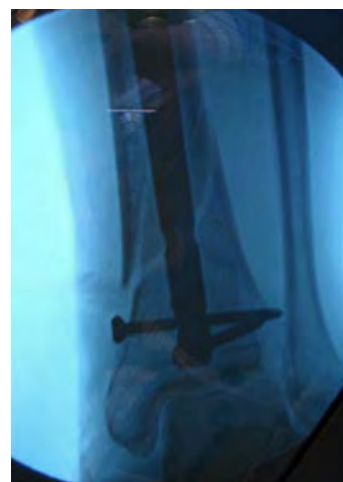
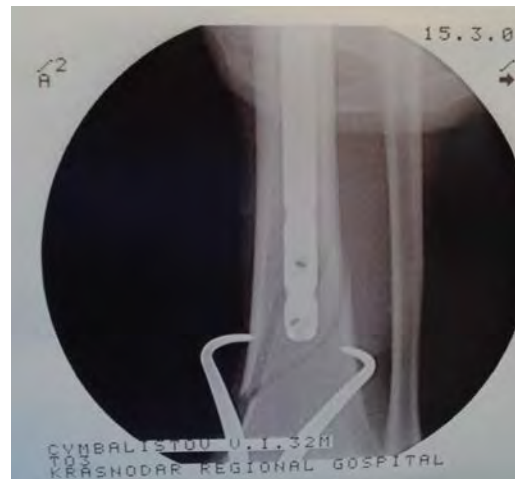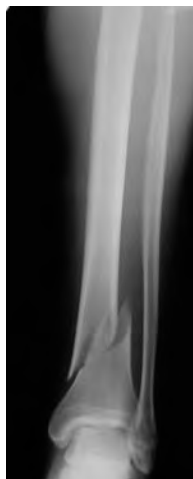Plating with
absolute stability
or **IMN** (2nd choice)







2nd choice (AKP syndrome)



Tibial shaft fractures. Algorithm of choosing surgical technique

High energy fractures

Low energy fractures

Splinting

Splinting or compression

Bad soft tissue

Good soft tissue

Poor bone quality

Good bone quality

IMN

Proximal part

Suprapatellar
or semiextended approach
Poller screws
ExFix for reduction

Middle part

Infrapatellar
approach

Distal part

Infrapatellar
approach
Poller screws
ExFix for reduction
Fibular fixation

IMN or Plating
(2nd choice)

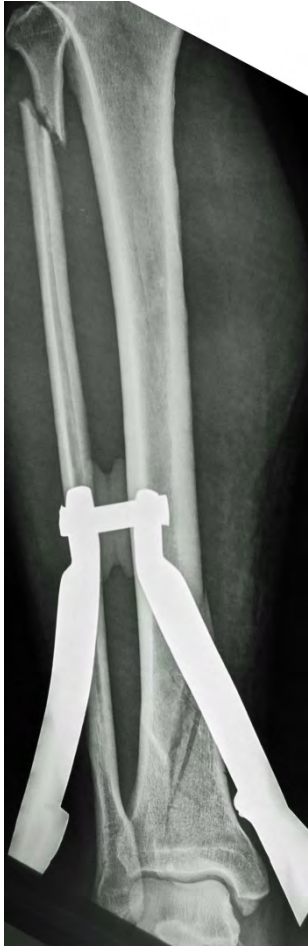IMN

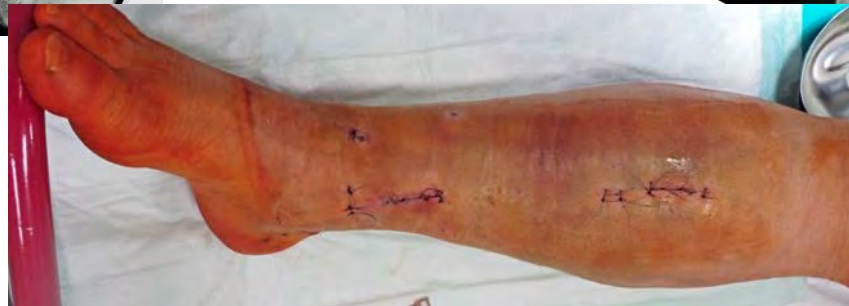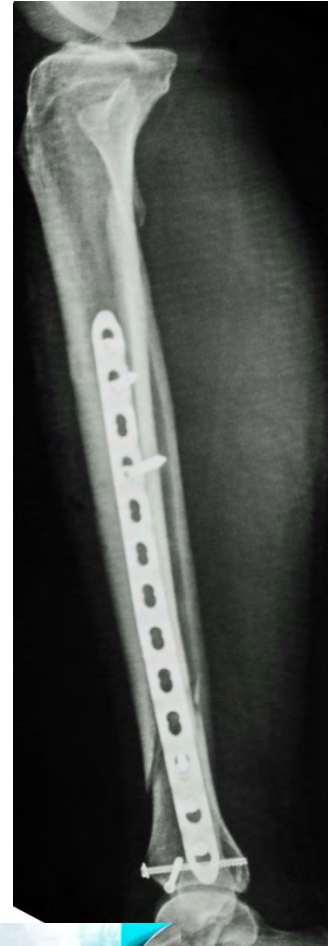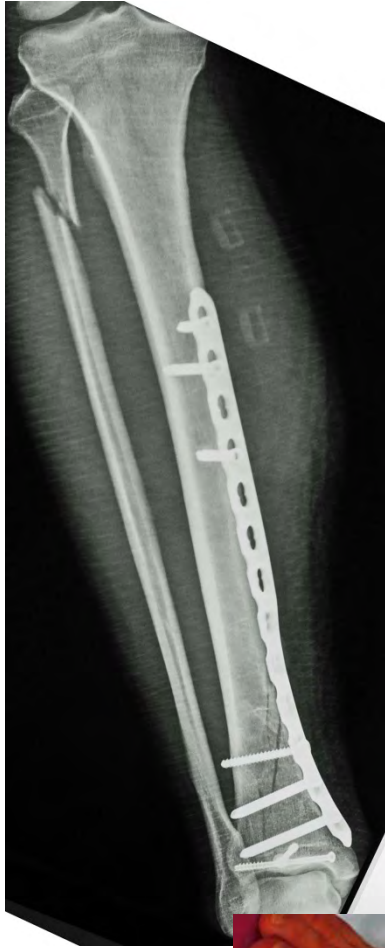Simple fracture

Plating with
absolute stability
or **IMN** (2nd choice)

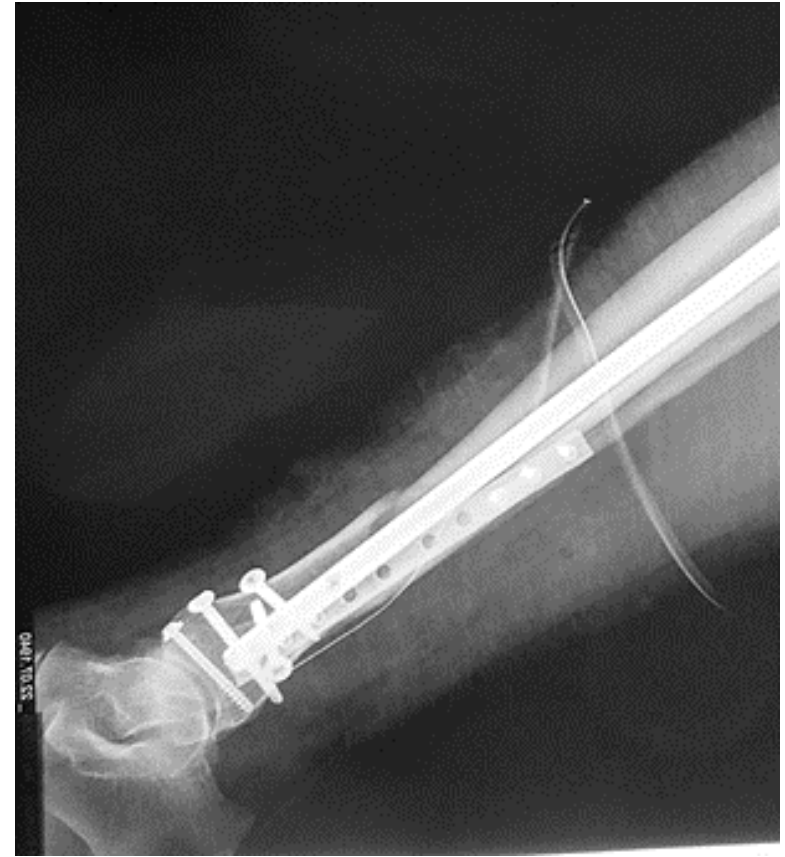
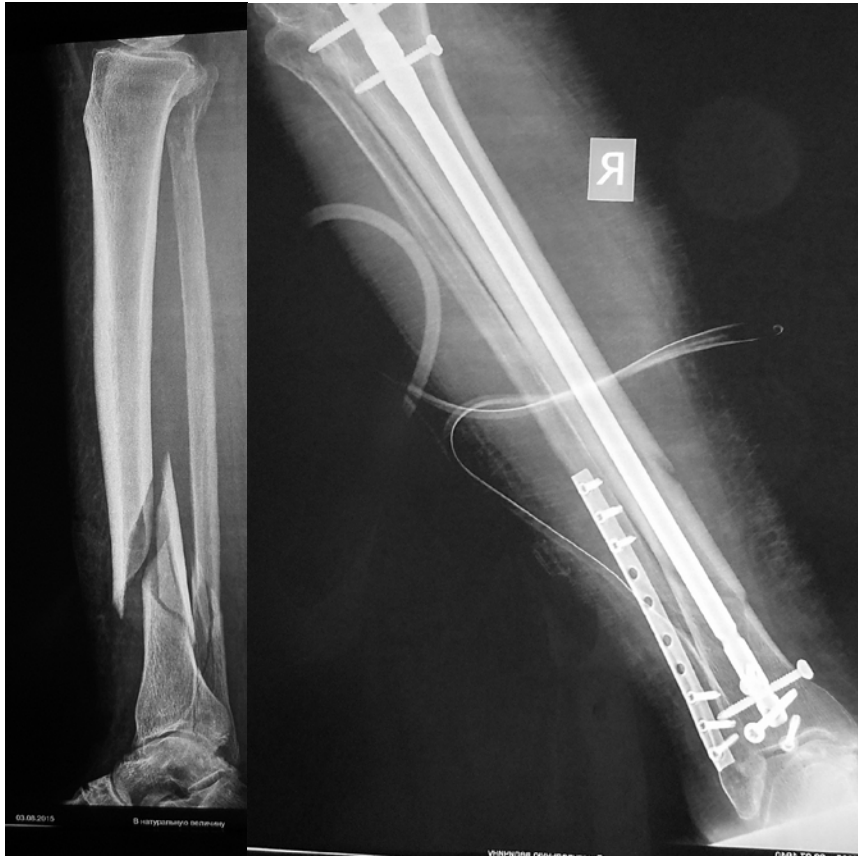Wedge, complex fracture

Plating with
relative stability
or **IMN** (2nd choice)





2nd choice (AKP syndrome)



Tibial shaft fractures. Algorithm of choosing surgical technique

High energy fractures

Low energy fractures

Splinting

Splinting or compression

Bad soft tissue

Good soft tissue

Poor bone quality

Good bone quality

IMN

Proximal part

Suprapatellar
or semiextended approach
Poller screws
ExFix for reduction

Middle part

Infrapatellar
approach

Distal part

Infrapatellar
approach
Poller screws
ExFix for reduction
Fibular fixation

IMN or Plating
(2nd choice)

IMN

Simple fracture

Plating with
absolute stability
or **IMN** (2nd choice)

Wedge, complex fracture

Plating with
relative stability
or **IMN** (2nd choice)

Conclusion

IMN is mechanically superior and miniinvasive surgical procedure

Anterior Knee Pain syndrome is still a problem for nailing

New surgical approaches don't solve all problems following to the nailing

Plating has benefits for proximal and distal low- energy shaft fractures

Choice of surgical technique is based on:

- energy of the injury, soft tissue conditions, bone quality, fracture pattern and location of fracture

Take-home message

- There is **no gold standard** for all tibial shaft fractures
- All points that we discussed during this presentation should be considered for choosing appropriate surgical technique

Take-home message

- There is **no gold standard for all tibial shaft fractures**
- All points that we discussed during this presentation should be considered for choosing appropriate surgical technique